

GENERAL PRINCIPLES

Thoracotomy performed to

- Evacuate pericardial tamponade
- Control hemorrhage from heart, lung, or vessel
- Cross-clamp descending thoracic aorta to improve coronary/cerebral arterial blood flow
- Allow for internal cardiac massage

INDICATIONS

- Recent prehospital cardiac arrest in a patient with a precordial wound
- Cardiac arrest in a trauma patient occurring on arrival in the emergency department, during resuscitation or observation
- Profound hypotension (blood pressure [BP] <70 mm Hg) due to a truncal wound in an unconscious patient, and distant or unavailable operating room (OR)

SUGGESTED OPERATIVE APPROACH

- Intubate
- Left thoracic wound: left anterolateral thoracotomy at the lower edge of the male nipple
- Right thoracic wound: right anterolateral thoracotomy, extend to the left if necessary
- Supraclavicular wound: thoracotomy above the male nipple or above the female breast in 3rd or 4th intercostal space

GENERAL OPERATIVE APPROACH

INCISION

Left anterolateral thoracotomy incision in the male. In the female, the breast is retracted upward before the incision is performed. The dotted line represents a possible extension into a bilateral anterolateral thoracotomy (left). The position of the chest wall retractor after completing a left anterolateral thoracotomy (right).

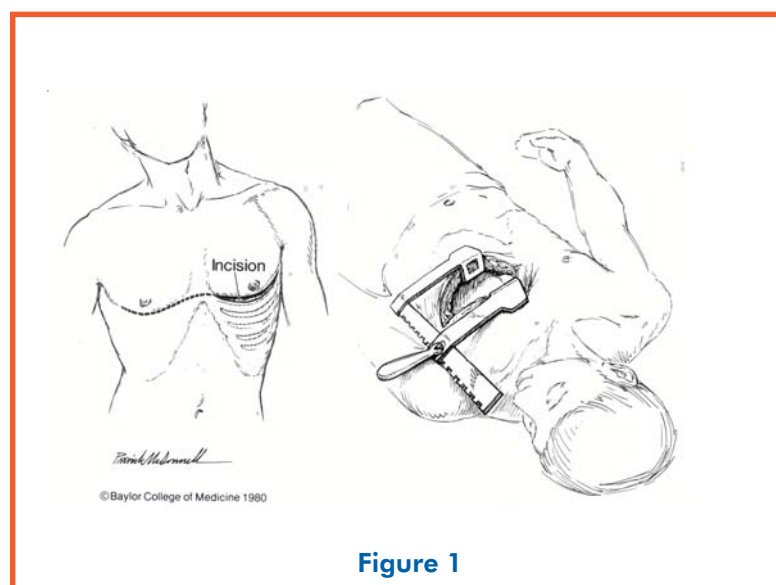
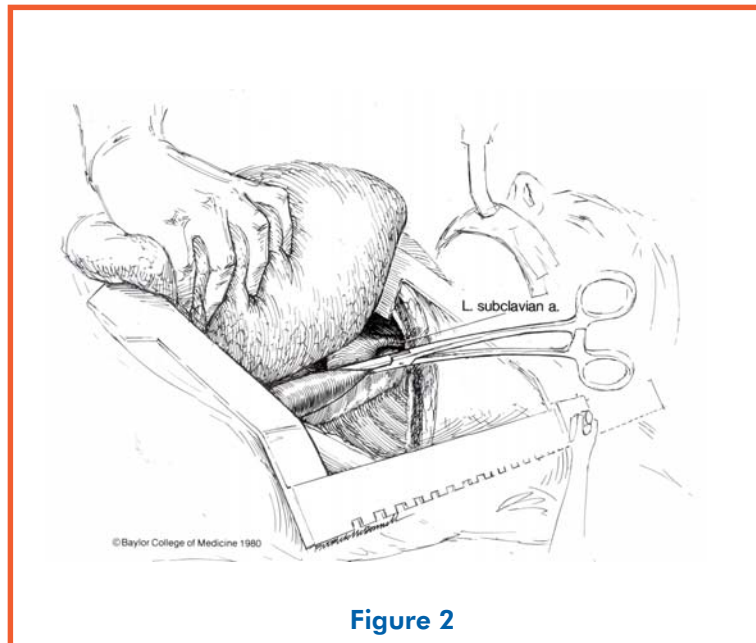


Figure 1

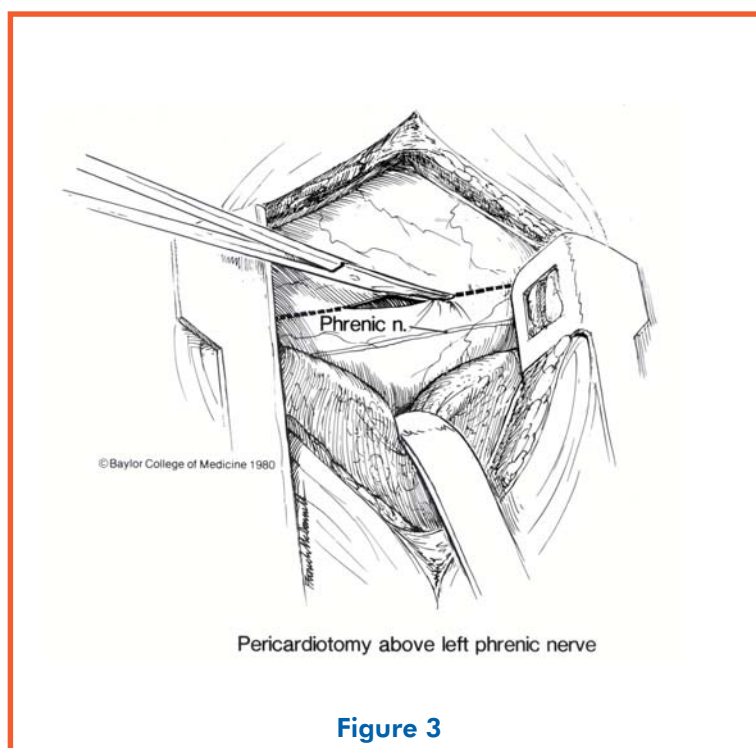
CROSS-CLAMP DESCENDING THORACIC AORTA

After lifting the left lung, the descending thoracic aorta is exposed and clamped with an aortic clamp. In the presence of tamponade, many surgeons perform pericardiotomy before this maneuver.



PERICARDIOTOMY TO ALLOW FOR RELEASE OF TAMPONADE, CARDIAC REPAIR, OR INTERNAL MASSAGE

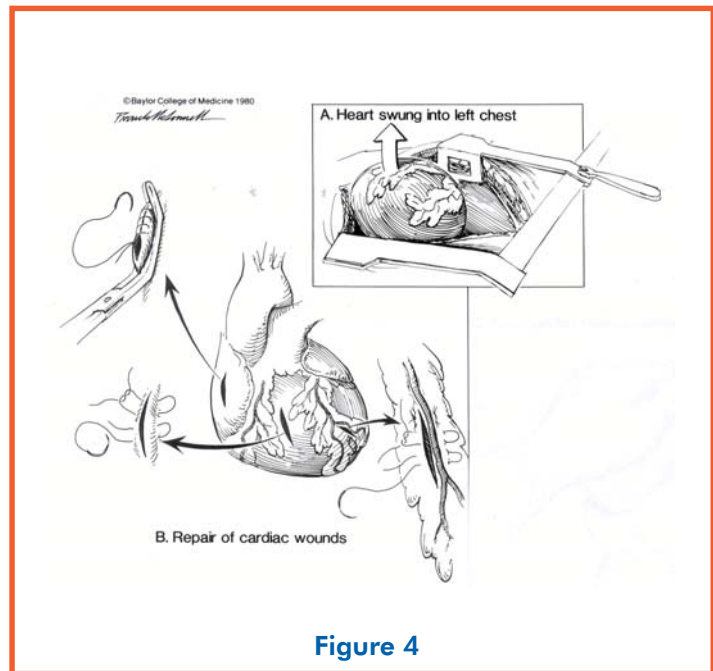
Pericardiotomy is performed parallel and anterior to the left phrenic nerve.



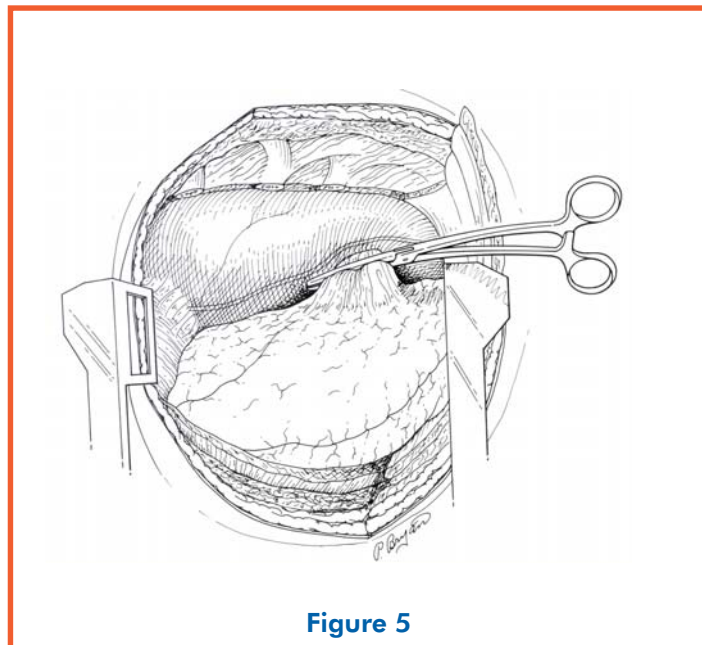
SPECIFIC OPERATIVE APPROACHES

REPAIR OF HEART

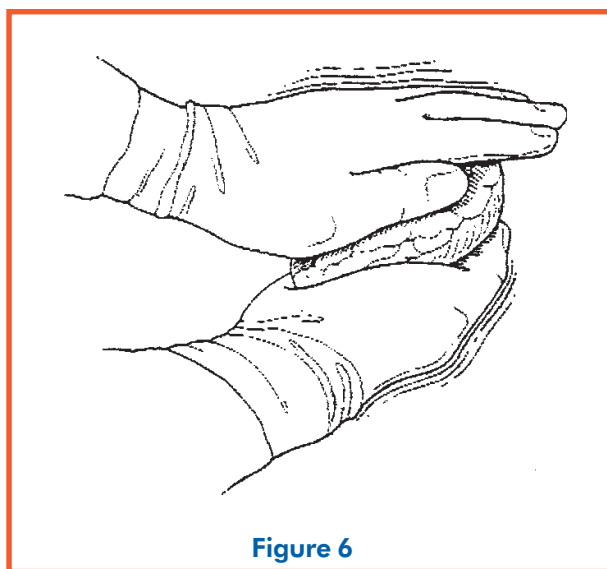
- Digital occlusion of lac
- Satinsky clamp for atrial wounds
- Interrupted sutures
- Wounds adjacent to coronaries:
Sutures under the bed of the artery



CROSS-CLAMP PULMONARY HILUM FOR MAJOR PULMONARY HEMORRHAGE



TWO-HANDED INTERNAL CARDIAC MASSAGE AVOIDS PERFORATION OF RIGHT VENTRICLE BY SURGEON'S THUMB



AT THORACOTOMY

NECESSARY EQUIPMENT

- Thoracotomy tray
- Polypropylene or large braided sutures with Teflon pledgets
- Advanced cardiac life support (ACLS) medications
- Paddles for internal defibrillation (applied to heart and discharged at 10 J—to start)

SALVAGE IS UNLIKELY

- Heart is in asystole when pericardium is opened
- With the descending thoracic aorta cross-clamped, BP cannot be maintained
- Air is present in coronary arteries

SALVAGE IS POSSIBLE—MOVE PATIENT TO THE OR

- Tamponade relieved and cardiac wound controlled by sutures, staples, or balloon in defect
- Hemorrhage from heart, lung, or subclavian vessels controlled, and systolic BP >70 mm Hg

TRANSPORT TO OR

- Call OR
- Coordinate transport
- Oxygenate/ventilate during transport
- Attach to transport monitor
- Leave chest wall retractor in place
- Cover head/body with warm sheets

Illustrations from Baylor University School of Medicine. Used with permission.