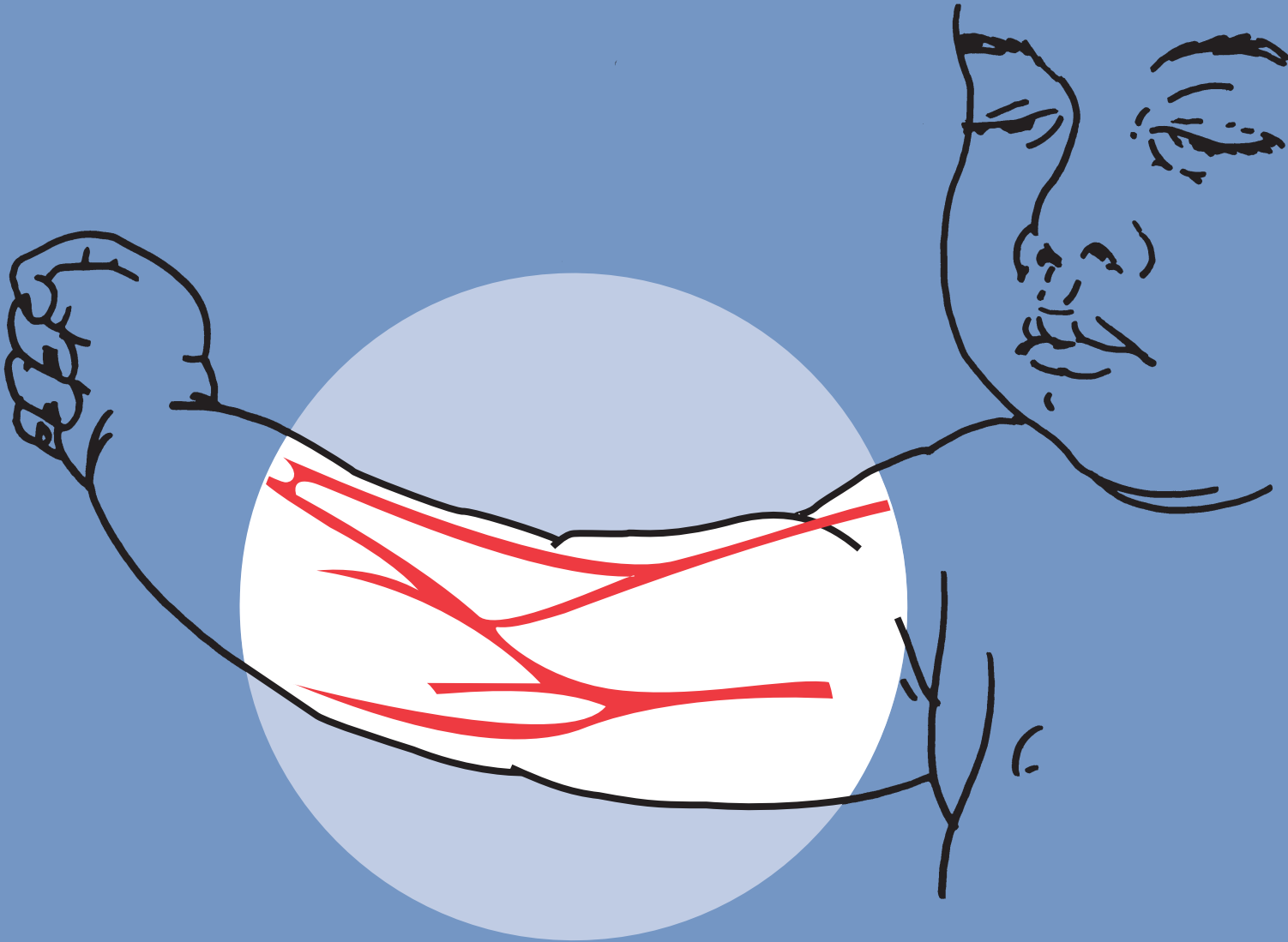


Emergency Vascular Access in Children

American College of Surgeons
Committee on Trauma
September 1999



Emergency Vascular Access in Children

This publication is designed to offer information suitable for use by an appropriately trained physician. The information provided is not intended to be comprehensive or to offer a defined standard of care. The user agrees to release and indemnify the American College of Surgeons from claims arising from use of the publication.

©1999 American College of Surgeons

David P. Mooney, MD, FACS, FAAP

Principles

- Obtain IV access on arrival in all children with a potentially significant injury or illness
- Prefer: 2 short, large diameter peripheral lines
- If 3 peripheral IV attempts not successful within 90 seconds, perform advanced method
- The advanced methods described below should only be performed by personnel with adequate training and experience in performing the procedures in children
- Replace advanced lines once patient stable

Peripheral IV

- Dorsal hand and greater saphenous veins preferred sites
- Immobilize extremity before attempt
- Use largest cannula vessel will allow
- Monitor site frequently

Intraosseous

- For children ≤ 6 years of age
- Anteromedial tibia, 1.5 cm below tibial tuberosity
- Ensure fluids infuse freely by gravity before infusing by pump. If not, do not use.
- May use for resuscitation meds
- Secure needle, monitor well
- Remove within 6 hours

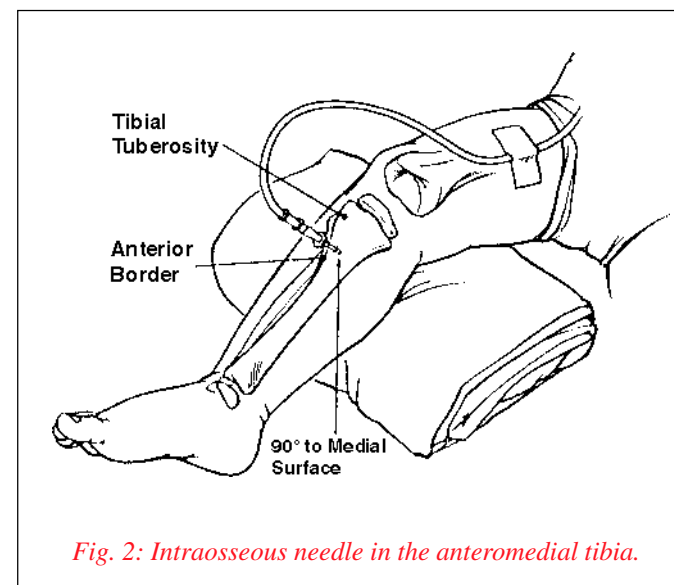
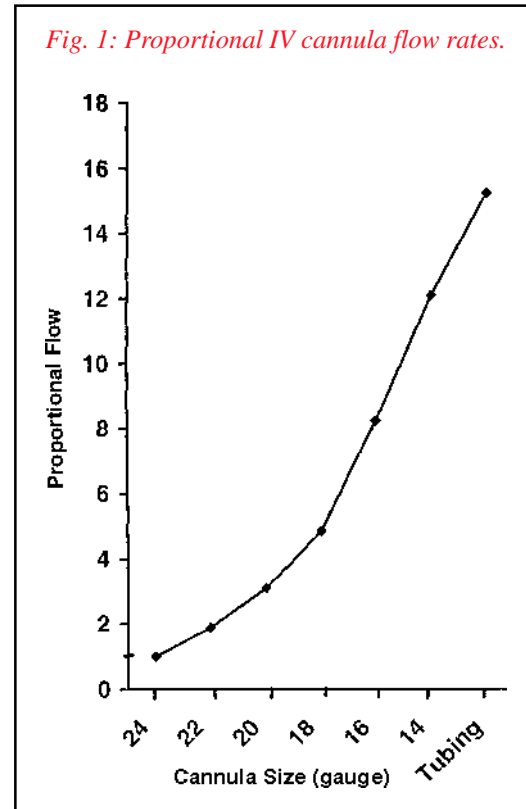


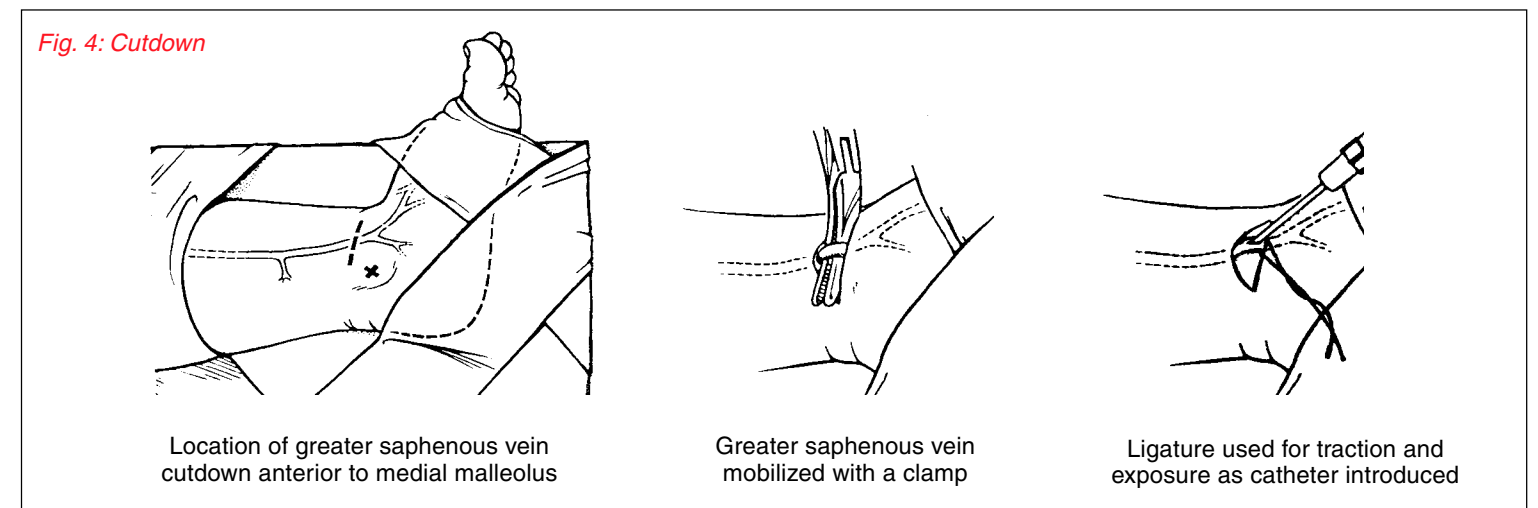
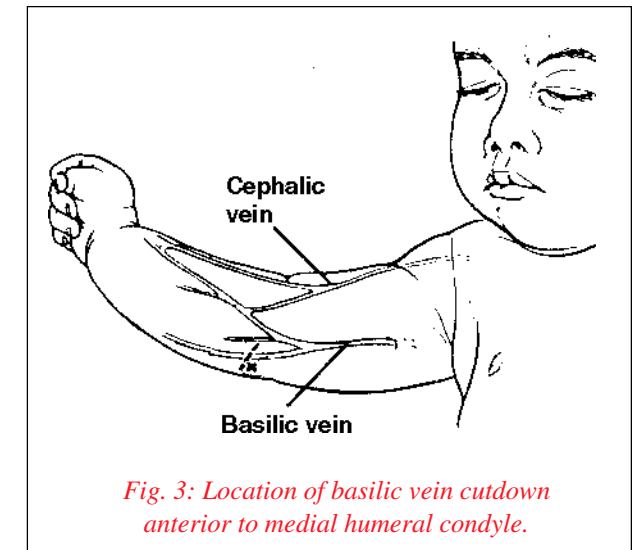
Fig. 2: Reproduced with permission. *Pediatric Advanced Life Support*, 1997. Copyright American Heart Association.

Fig. 3,4,5: Source: *Pediatric Advanced Life Support*, American Heart Association, 1997.



Cutdown

- Greater saphenous or basilic veins
- Cephalic or basilic vein if potential abdominal trauma
- Steps: immobilize area, sterilize, anesthetize, then incise skin, mobilize vein with clamp, loop vein with ligature, insert catheter, secure catheter, dress site
- Broadest, shortest catheter vein will allow



Central Line

- High complication rate in children. Should be attempted only after other techniques have failed, and only by those with experience in the procedure in children
- Femoral route preferred
- Seldinger technique
- Secure catheter, apply occlusive dressing
- Monitor extremity closely for signs of vascular compromise

